

Wound-Healing Potential of Oil of *Hypericum perforatum* in Excision Wounds of Male Sprague Dawley Rats

Shivananda B. Nayak,^{1,*} Kubra-Isik,² and Julien R. Marshall²

¹Department of Preclinical Sciences, Faculty of Medical Sciences, University of the West Indies, Mount Hope, Trinidad and Tobago.

²Department of Stem-Cell and Tissue Engineering, Tbilisi State Medical University, Tbilisi, Georgia.

Objective: To evaluate the wound-healing activity of oil of *Hypericum perforatum* (*St. John's wort*), in excision wounds of male white rats.

Approach: The current methods of wound management involve the use of antibiotic creams. The search for more natural materials for the purpose of healing of wounds has led to the discoveries of potential agents prepared from plant extracts. *Hyperforin* and *Hypericin* are important phytochemical constituents found in *H. perforatum*, which have been highlighted for their antimicrobial, antiviral, and anti-inflammatory properties in recent times. Therefore, we have attempted to explore the wound-healing activity of oil obtained from *H. perforatum*.

Results: *H. perforatum* oil emulsion has been demonstrated to have significant wound-healing potential as compared with mupirocin ointment and petroleum jelly (Vaseline). Animals treated with *H. perforatum* showed a 97% (18.9 mm²/day) reduction in wound area as compared with animals treated with mupirocin (68%) (12.8 mm²/day) and animals treated with Vaseline (69%) (13.7 mm²/day). X-ray analysis of skin of animals treated with *H. perforatum* showed a significant increase in angiogenesis as compared with other groups in the study.

Innovation: This study identified the wound-healing activity of oil of *H. perforatum*.


Conclusion: The findings of this study support the wound-healing potential of *H. perforatum* along with other therapeutic uses.

Keywords: wound healing, excision wound, mupirocin, *Hypericum perforatum*

INTRODUCTION

WOUND HEALING CONTINUES to be an area of intense research and development, as it relates to using and finding suitable material, synthetic or biologic, otherwise in the adequate management of wounds. The current methods of wound management involve the use of antibiotic creams, L-Mesitran (honey) cream, collagenase-based (enzymatic) chemical debridement, surgical debridement, and vacuum negative pressure dressings,

all of which promote the development of granulation tissue, while slowing the development of inflammation or production of exudate.¹ All of the highlighted methods come with significant benefits to the user but may also possess some disadvantages, for example, the relative cost of materials or unwanted side effects of the chemicals used. The search for more natural materials for the purpose of healing of wounds has led to the discoveries of potential agents such as



Shivananda B. Nayak, MSc, PhD,
NRCC-CC

Submitted for publication June 25, 2017.
Accepted in revised form July 23, 2017.

*Correspondence: Department of Preclinical Sciences, Faculty of Medical Sciences, The University of the West Indies, Mount Hope, Trinidad and Tobago
(e-mail: shivananda.nayak@sta.uwi.edu).

Ethanollic carica papaya seeds extract, *Vitis vinifera* (grape), *Vaccinium macrocarpon* (cranberry), and *ethanollic extract of Kalanchoe pinnata* leaf.^{2–4} Much is known about *Hypericum perforatum*; it grows as a flowering plant (weed) in temperate regions of the world with cultivation for medicinal purposes in places such as China, Eastern Turkey, and Eastern Europe. *H. perforatum* functions as a potent antidepressant agent and is a known CYP3A4 inducer. *Hyperforin* and *Hypericin* are important phytochemical constituents that have been highlighted for their antimicrobial, antiviral, and anti-inflammatory properties in recent times.⁵

CLINICAL PROBLEM ADDRESSED

Most of these phytochemicals have been extracted from ethanolic extracts of the aerial components of *H. perforatum*. Thus far little work has been reported that demonstrates the effects of oils of the plants. The goal of this study was to explore and demonstrate the effects of *H. perforatum* oils for the management of excision wounds in a rat model.

MATERIALS AND METHODS

Plant and extract preparation

H. perforatum oil (250 mL) was purchased from a local supplier for the experiment; it was supplied by a local grower of the plant in eastern Turkey. The oil was collected in 500 mL containers, separated into 30 mL aliquots, and then mixed with an equal volume of liquefied petroleum jelly. *Hypericum* oil (30 mL) and petroleum jelly (30 mL) was mixed in the ratio of 1:1 and was allowed to cool to room temperature and then refrigerated, thereby solidifying the *H. perforatum* extract.

Animals preparation

Adult healthy male white rats were used for the experiment. The rats were housed individually and fed a diet of standard animal feed stock with adequate access to water, *ad libitum*. The rats were divided into three groups. Control group (A) was treated with petroleum jelly, standard group (B) was treated with mupirocin ointment, and experimental group (C) was treated with *H. perforatum*+ petroleum jelly (1:1). Each group contained six rats ($N=6$). Before the infliction of each excision wound, the rats received 2–4 mg/kg body weight of diazepam, a muscle relaxant intraperitoneally, followed by 1.5 cc of subcutaneous (lidocaine 2%) on the dorsum of the animal (Strict laws of the Republic of Georgia restrict the use of ketamine analgesic). The animals were observed for any infection and those found to be infected were excluded from the study.

An acute toxicity study was conducted for the oil by the stair-case method.⁶ The LD₅₀ of the oil was found to be 100 mg/kg body weight. One-tenth of the dose was selected for the evaluation of wound-healing activity, that is, 10 mg/kg body weight.

Excision wound model

Before inflicting of excisional wounds, the animals were anesthetized according to the already mentioned procedure. Excision wounds were created using the protocol described by Morton and Malone.⁷ The dorsal fur of the animals was shaved using an electrical clipper and an outline of the wound to be excised was made with a black marker. A full thickness excision wound was created with an average area of 250 mm² and 2 mm deep using a toothed forceps, a surgical blade, and tissue scissors. The animals were randomly divided into three groups with $N=6$

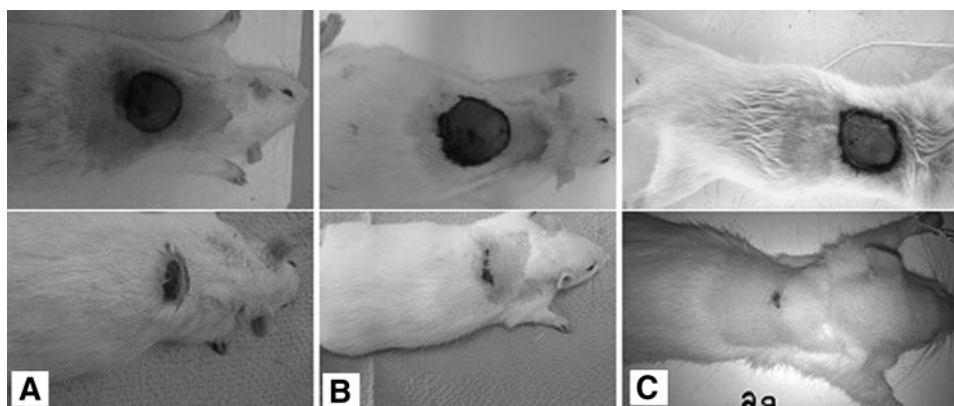


Figure 1. (A) Control group on days 1 and 11 treated with petroleum jelly, (B) standard group treated with mupirocin ointment, (C) excision wound of test group treated with *Hypericum perforatum*.

rats in each group: group A animals were treated with petroleum jelly, group B animals were treated with 2% mupirocin ointment, and group C animals were treated with a daily generous application of *H. perforatum* (10 mg/kg body weight) with petroleum jelly. Treatment duration was 11 days. Care was taken to avoid variation in the dosage throughout the course of the experiment. The rate of wound closure was recorded for 11 days by tracing the wound area on every other day (1, 3, 5, 7, 9, and 11) using transparent paper and a permanent marker. The areas traced

were measured using graph paper and recorded accordingly.

X-ray determination of skin

Two animals were used from the test group. The animals were given an intraperitoneal dose of 2–4 mg diazepam (muscle relaxant). Intra-abdominal access was achieved through 11–2 cm medial incision with a 10 surgical blade; intra-abdominal organs were retracted to access the abdominal aorta. Contrast dye was injected into the abdominal aorta of the live animal and allowed to perfuse through-

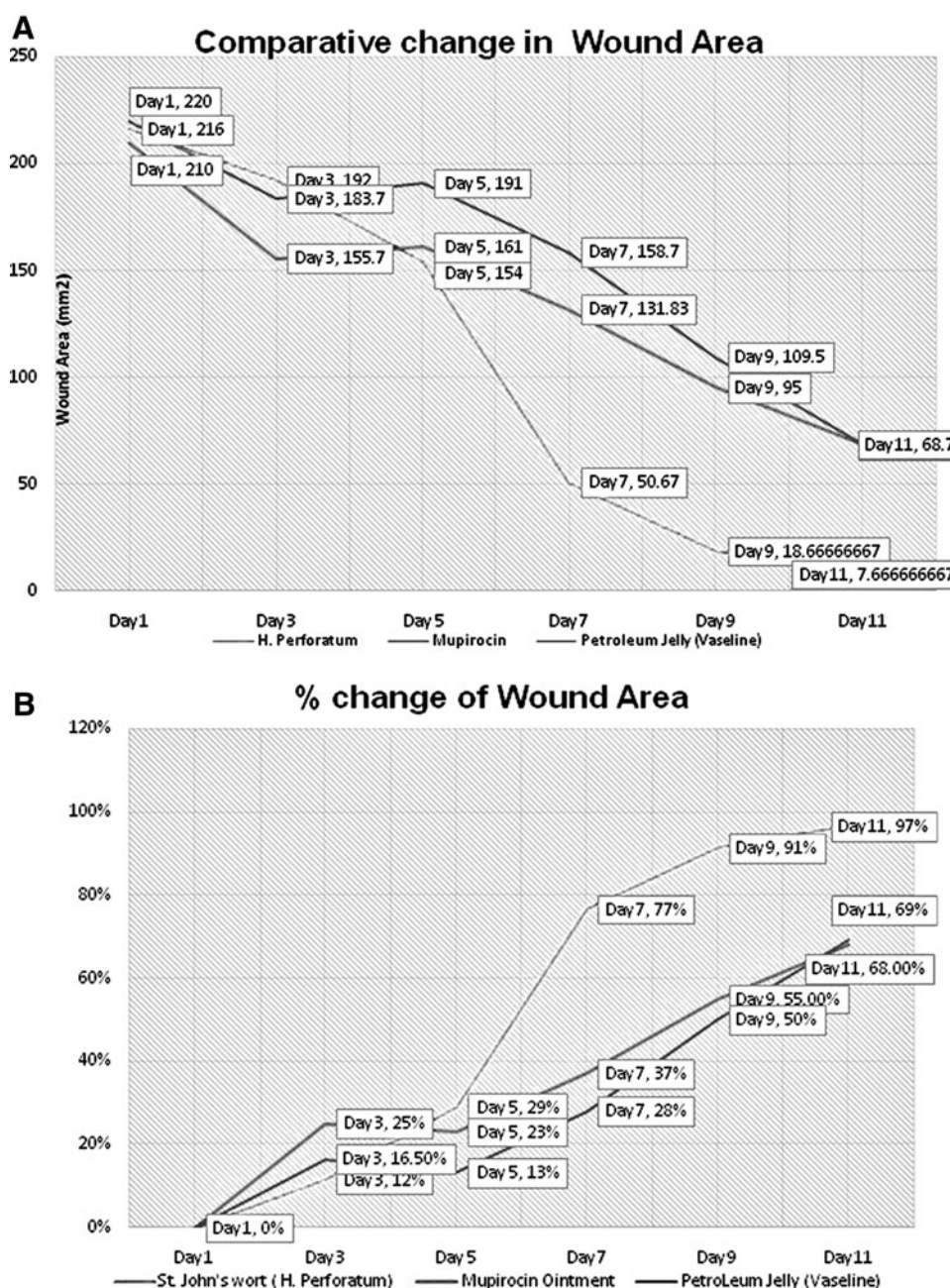


Figure 2. (A) Comparative change in wound area, (B) percentage wound area closure.

out the animal for 5–10 min. The animals were subsequently sacrificed and the dorsal skin was removed. A portable Biox Dental X-ray camera was used to capture images of the skin of selected rats.

Histology study

Granulation tissue was collected on the 11th day of the study from animals in the control group and from animals treated with *H. perforatum* for histological analysis. For better appreciation of collagen deposition, slides were treated with hemotoxylin and eosin (H&E) stain. Fibers were stained (purple) with H&E.

Statistical analysis

The means of wound area measurements between groups at different time intervals were compared using one-way ANOVA and descriptive test followed by Tukey's *post hoc* test. Data were analyzed using SPSS (version, 16 Chicago) and *p* values were all set at <0.05 for all analyses.

RESULTS

On day 11, there was a significant increase in the rate of wound healing in *H. perforatum*-treated animals as compared with animals treated with mupirocin and Vaseline, respectively (Fig. 1). Significant progressive reduction in wound area was observed throughout the study with the experimen-

tal group, showing a 97% reduction in wound area on day 11, as compared with that in the standard group 68% and in the control group 69% (Fig. 2A, B). X-ray analysis revealed greater angiogenesis in the test group (Fig. 3A) than in the control group (3B).

Histological analysis of H&E-stained granulation tissue revealed that the experimental group had dense bundles of collagen fibers, fibroblast cells, new blood vessels, and hair follicles (Fig. 4).

DISCUSSION

H. perforatum has been shown to exhibit significant wound-healing potential according to this study. Accelerated rate of wound healing was observed with animals treated with *H. perforatum* as compared with animals treated with petroleum jelly (control) and mupirocin ointment. Wölfle *et al.*⁸ demonstrated significant antimicrobial activity of *Hyperforin*, in a study that showed resistance against methicillin-resistant *Staphylococcus aureus*, as well as gram-negative and gram-positive species. Antimicrobial activity is of value because any wound-healing agent that shortens the length of the inflammatory phase increases the rate of progression of subsequent healing phases. *H. perforatum* extracts have been demonstrated to be potent inhibitors of

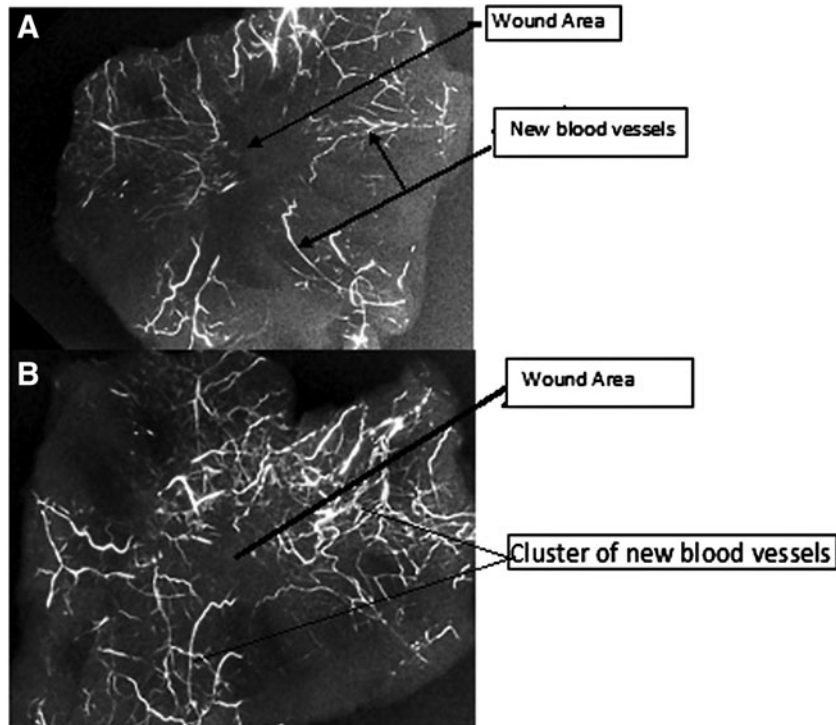


Figure 3. (A) X-ray image of granulation tissue at day 11, petroleum jelly-treated control group and (B) granulation tissue, at day 11 of *Hypercium perforatum*-treated test group).

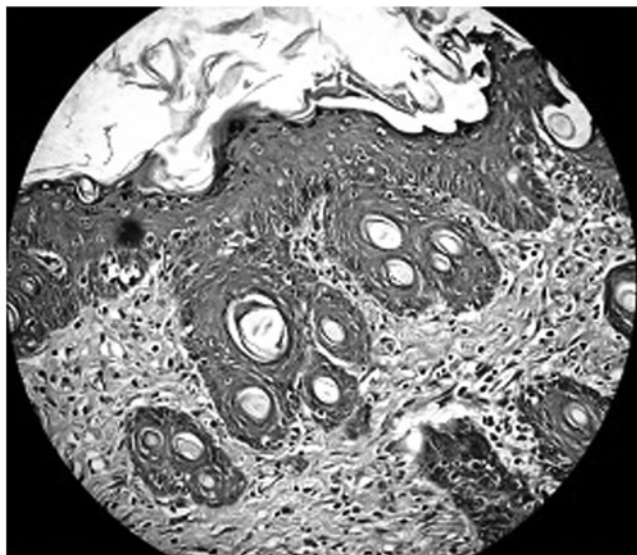


Figure 4. Granulation tissue at day 11—*Hypercium perforatum*-treated group.

5-lipoxygenase, cyclooxygenase-1, interleukin-gamma, and interleukin-6 in reported studies.⁸

Hyperforin and *Hypericin* have been shown to be the chief phytochemicals involved with significant anti-inflammatory activity comparable with indomethacin and other anti-inflammatory drugs.⁸ Ozturk *et al.*⁹ have shown that *Hypericin* contained in aerial segments of *H. perforatum* significantly affected the proliferation phase of the wound-healing cascade, contributing to increased fibroblast proliferation, maturation, and subsequent collagen deposition. This was comparable to the mechanism of *Centella asiatica*, a herb that has medicinal properties. *H. perforatum* has demonstrated a paradoxical effect when its proangiogenic phyto-

Proposed activity of *Hypercium Perforatum*

Inflammatory phase

Hyperforin (anti-microbial)

Hypericin (anti-inflammatory)

Proliferation Phase

Hypericin + pseudohypericin (proliferation of fibroblast & epithelization)
Pro-angiogenesis?

Epithelization phase

Flowchart showing the possible wound healing mechanism of *H.perforatum*

KEY FINDINGS

We identified and proved the accelerated rate of wound-healing activity of *H. perforatum*.

chemical components are evaluated. In the granulation phase, adequate blood supply is paramount, and as such phytochemical effects with proangiogenic activity are expected; however, *H. perforatum* extracts have shown significant amounts of flavonoids (namely quercetin that has been shown to have potent anti-VEGF activity), which can explain the anticancer potential found in this extract.

Of the phytochemicals evaluated in extracts of *H. perforatum*, *Hyperforin*, *Hypericin*, and *pseudohypericin* were found to be the most biologically active components. *H. perforatum* has been shown to be of clinical value in the management of venous ulcers and pressure ulcers. However, the data remain inclusive and the phytochemical contribution to the mentioned activity has not been isolated to only *H. perforatum*.^{10,11} The wound-healing potential of *H. perforatum* seems to exhibit its effect in modulating the inflammatory and proliferative phases of the healing cascade, with *Hypericin*, *Hyperforin*, and *pseudohypericin* being the most active compounds in the respective phases (refer flow chart).

INNOVATION

This study identified and proved the accelerated rate of wound-healing activity of the oil of *H. perforatum* in a rat model.

ACKNOWLEDGMENTS AND FUNDING SOURCES

Authors would like to thank the technicians of both the institute where the work was carried out with their help. All authors declare that no funding was provided to carry out this research.

AUTHOR DISCLOSURE AND GHOSTWRITING

All authors declare that there is no competing financial interests with this research.

ABOUT THE AUTHORS

Shivananda B. Nayak, MSc, PhD, NRCC-CC, is presently working as Professor and Head, Department of Preclinical Sciences, The University of the West Indies, Faculty of Medical Sciences, Trinidad and Tobago. He has published more than 120 articles on wound healing and type 2 diabetes. **Julien R. Marshall, MBBS**, is a doctor practicing in Trinidad. **Kubra-Isik, MBBS**, is also a medical doctor.

REFERENCES

1. Rusak A, Rybak Z. New directions of research related to chronic wound healing. *Polim Med* 2013;43:199–204.
2. Nayak BS, Ramdeen R, Adogwa A, Ramsuhag A, Marshall JR. Wound-healing Potential of ethanolic extracts of carica papaya seeds. *Int Wound J* 2012;9:650–655.
3. Shivananda Nayak B, Dan Ramdath D, Marshall JR, Isitor G, Xue S, Shi J. Wound Healing properties of the Oils of *Vitis vinifera* and *Vaccinium macrocarpon*. *Phytother Res* 2011;25:1201–1208.
4. Nayak BS, Marshall JR, Isitor G. Wound healing potential of ethanolic extract of *Kalanchoe pinata* Lam. leaf-A preliminary study. *Indian J Exp Biol* 2010;48:572–576.
5. Reichling J, Weseler A, Saller R. A current review of the antimicrobial activity of *Hypericum perforatum* L. *Pharmacopsychiatry* 2001;34(Suppl 1): 116–118.
6. Jalalpure SS, Patil MB, Prakash NS, Hemalatha K, Manvi FV. Hepatoprotective activity of fruits of *Piper longum* L. *Indian J Pharm Sci* 200;65:363–366.
7. Morton JJP, Malone MH. Evaluation of vulnerary activity by an open wound procedure in rats. *Arch Int Pharmacodyn* 1972;196:117–126.
8. Wölfle U, Seelinger G, Schempp CM. Topical application of St. John's Wort. *Planta Med* 2013;80:109–120.
9. Ozturk N, Korkmaz S, Ozturk Y. Wound-healing activity of St. John's Wort (*Hypericum perforatum* L.) on chicken embryonic fibroblast. *J Ethnopharmacol* 2007;111:33–39.
10. Lomagno P, Lomago RC. Activity of *Hypericum perforatum* Oil in the treatment of bed sores in old people. *Fitotherapia* 1979;50:201–205.
11. Lavagna SM, ecci D, Chimenti P. Efficacy of *Hypericum* and *calendula* Oils in the epithelial reconstruction of surgical wounds in the childbirth with caesarean section. *Farmaco* 2001;56:451–453.